
Endoscopic four-hands technique for pituitary tumours

PERSPECTIVES

MARKUS WIEDMANN

markus.wiedmann@ous-hf.no

Markus Wiedmann PhD, senior consultant in the Department of Neurosurgery, Oslo University Hospital.

The author has completed the ICMJE form and declares no conflicts of interest.

IDA OLESRUD

Ida Olesrud, specialty registrar (part 1) at Akershus University Hospital, previously worked in the Department of Neurosurgery, Oslo University Hospital.

The author has completed the ICMJE form and declares no conflicts of interest.

ASLAN LASHKARIVAND

Aslan Lashkarivand, specialty registrar in neurosurgery, Department of Neurosurgery, Oslo University Hospital.

The author has completed the ICMJE form and declares no conflicts of interest.

SINAN DHEYAULDEEN

Sinan Dheyauldeen PhD, senior consultant in the ENT Department, Oslo University Hospital and associate professor in the Institute of Clinical Medicine, University of Oslo.

The author has completed the ICMJE form and declares no conflicts of interest.

ANSGAR HECK

Ansgar Heck PhD, senior consultant in the Specialised Endocrinology Section, Oslo University Hospital.

The author has completed the ICMJE form and declares no conflicts of interest.

JON BERG-JOHNSEN

Jon Berg-Johnsen PhD, senior consultant in the Department of Neurosurgery, Oslo University Hospital and professor in the Institute of Clinical Medicine, University of Oslo.

The author has completed the ICMJE form and declares no conflicts of interest.

DANIEL DAHLBERG

Daniel Dahlberg PhD, senior consultant in the Department of Neurosurgery, Oslo University Hospital.

The author has completed the ICMJE form and declares no conflicts of interest.

Tumours in the pituitary fossa region can be resected by endoscopic transnasal surgery using a four-hands technique. The technique, which is atraumatic, safe and minimally invasive, should be the first-line treatment for pituitary tumours and certain skull-base tumours.

The surgical microscope has traditionally been an indispensable tool for neurosurgeons. The microscope enables surgeons to work under high magnification with good light and use both hands at the same time for microsurgical dissection. The development of minimally invasive surgery, with more or less atraumatic surgical approaches, has led to increasing use of endoscopy, including within neurosurgery.

Tumours in and around the pituitary fossa are increasingly being resected with endoscopic transnasal surgery. The combination of an advanced microsurgical technique and the use of endoscopy requires two surgeons working together as one unit to ensure good workflow and optimal working conditions using the four-hands technique. A dedicated team with expertise in endoscopic and microsurgical neurosurgery must be established for this. It is our opinion that pituitary tumours and other suitable skull-base tumours in the sellar region should be predominantly resected with an endoscopic four-hands technique.

Tumours in the sella turcica region

Approximately 18 % of all primary brain tumours are located in and around the pituitary fossa, also known as the sella turcica [\(1\)](#). Most tumours in the sellar region are benign and grow slowly. Pituitary adenomas make up the largest group of sellar tumours. Other tumours in the sellar region are meningioma, craniopharyngioma, chordoma and chondrosarcoma.

«It is our opinion that pituitary tumours and other suitable skull-base tumours in the sellar region should be predominantly resected with an endoscopic four-hands technique»

Tumours with suprasellar growth can compress the visual system and impair both visual acuity and visual fields. The typical defect is bitemporal hemianopia. Even if the patient does not notice an impact on their vision, careful examination by an ophthalmologist is indicated if MRI demonstrates an involvement of the visual system. Surgical treatment is usually required if a tumour is impacting visual function. Preoperative hormone levels should also be investigated. Hormone-producing tumours can cause, for example, Cushing's disease, acromegaly or galactorrhoea, and should be evaluated by an endocrinologist. Most hormone-producing tumours are treated with surgery, either with curative intent or to reduce tumour volume as part of multimodal treatment.

Surgical treatment

The first transsphenoidal operation for pituitary tumour was performed over 100 years ago. The introduction of the surgical microscope in the 1970s contributed to safer and more atraumatic surgery. However, the long and narrow transnasal approach limited the amount of light, field of view and manipulation of instruments to the surgical field [\(2\)](#). Therefore, since 2000, increasing numbers of neurosurgical centres have moved over to endoscopic surgery for pituitary tumours [\(3\)](#).

The endoscope has a light source and optics in the tip of the surgical instrument, which improves the field of view of the tumour tissue and anatomic structures. Better visualisation can reduce the risk of injury to healthy pituitary tissue, adjacent blood vessels and nerves, as well as increase the extent of resection.

Introduction of endoscopic pituitary surgery

Endoscopic transsphenoidal resection of pituitary tumours has been the standard surgical method in the Department of Neurosurgery at Oslo University Hospital since 2007. Halvorsen et al. compared the first 238 patients who underwent surgery with an endoscopic technique with an equivalent population who underwent surgery with a surgical microscope, and found no significant difference in the rate of complications when the new technique was introduced [\(4\)](#).

The main challenge with the most common endoscopic technique – where a surgeon operates alone – is that the surgeon's left hand must be used to control the endoscope, leaving only one hand for dissection. Constantly switching between suction and other instruments with the operating right hand disrupts workflow, particularly in complicated cases. Complicated skull-base tumours require delicate bimanual dissection, and this 'two-hands technique' has been a limiting technical factor. The challenge has been addressed with the use of a

mechanical holding arm, meaning that the surgeon can operate with both hands. However, the fixed optics reduce depth perception and flexibility in the surgical field, and conflict arises with the constant movement of instruments.

Endoscopic four-hands technique

Modern endoscopic transsphenoidal surgery in the pituitary region and base of the skull requires dynamic camera manipulation and the option of operating with both hands. Therefore, internationally recognised centres performing surgery on pituitary and skull-base tumours have introduced a technique called the four-hands technique, as described for example by Castelnovo et al. in 2006 (2). In this technique, two surgeons work together to ensure optimal workflow, optics manipulation, visualisation and tumour dissection in a small and narrow surgical field. The technique requires the surgeons to work in coordination and be experienced in endoscopic and microsurgical techniques. This method has paved the way for transnasal surgery on increasingly complex and extensive lesions in the skull base (5–7).

«Two surgeons work together to ensure optimal workflow, optics manipulation, visualisation and tumour dissection in a small and narrow surgical field»

In the Department of Neurosurgery at Oslo University Hospital, we introduced the endoscopic four-hands technique in 2019. The technique allows delicate and precise dissection, not just of pituitary tumours, but also other and more complex skull-base tumours (5). The four-hands technique opens up new opportunities to tackle pathology in the sellar region and represents a paradigm shift for this type of procedure.

With the four-hands technique, one surgeon uses both hands for the microsurgical procedure. The second surgeon controls the endoscope for optimal visualisation and keeps the surgical field clean (Figures 1–3). The aim is to achieve the most radical tumour resection possible, which requires identification of the dissection plane between the tumour, normal pituitary gland and surrounding membranes. The endoscope can be inserted fully into the sella turcica to identify and preserve pituitary tissue and remove tumour tissue that would otherwise be difficult to access. This helps to achieve maximum tumour resection without harming normal pituitary function (see video).

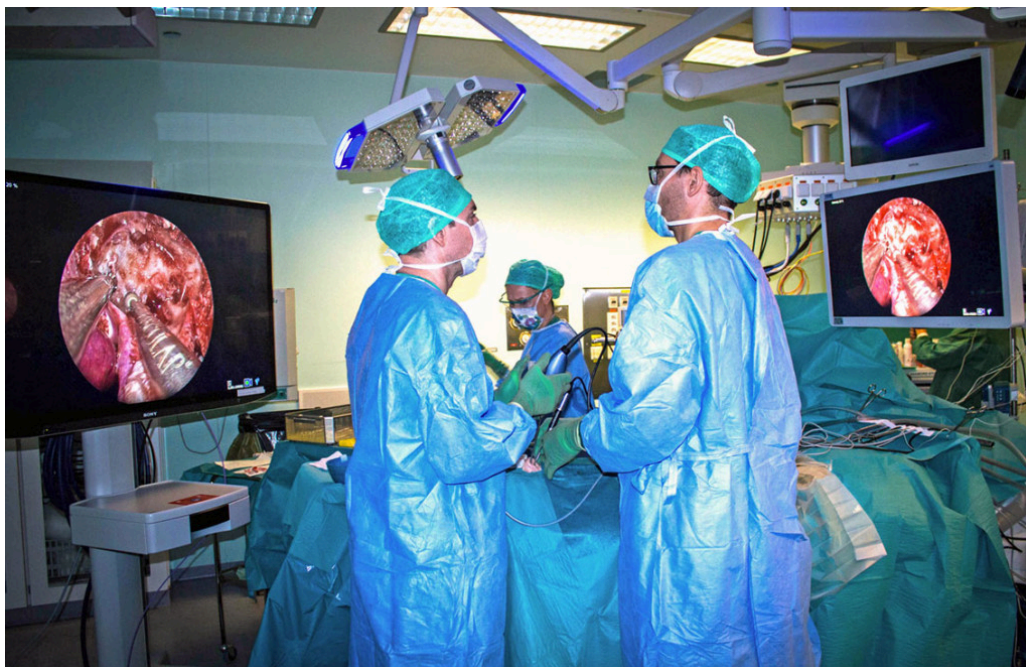


Figure 1 Overview image of the use of an endoscopic four-hands technique. The instruments are inserted via both nostrils. The surgeons regularly switch roles in the surgical field.

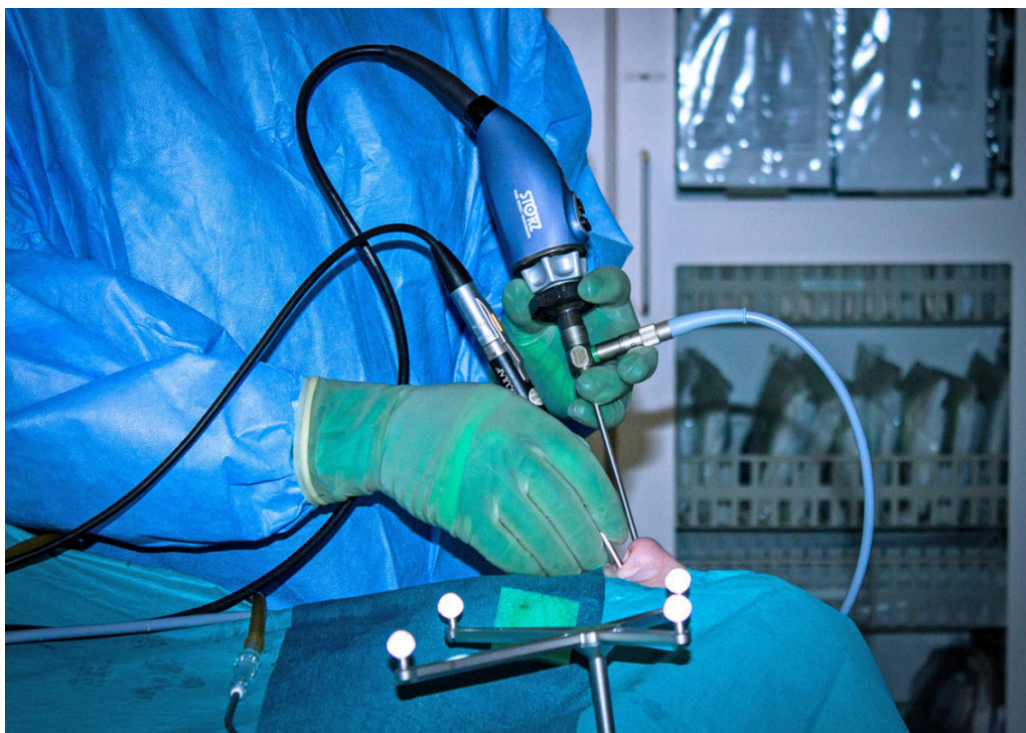


Figure 2 Endoscopic two-hands technique. The surgeon controls the camera with their left hand and operates with their right hand.

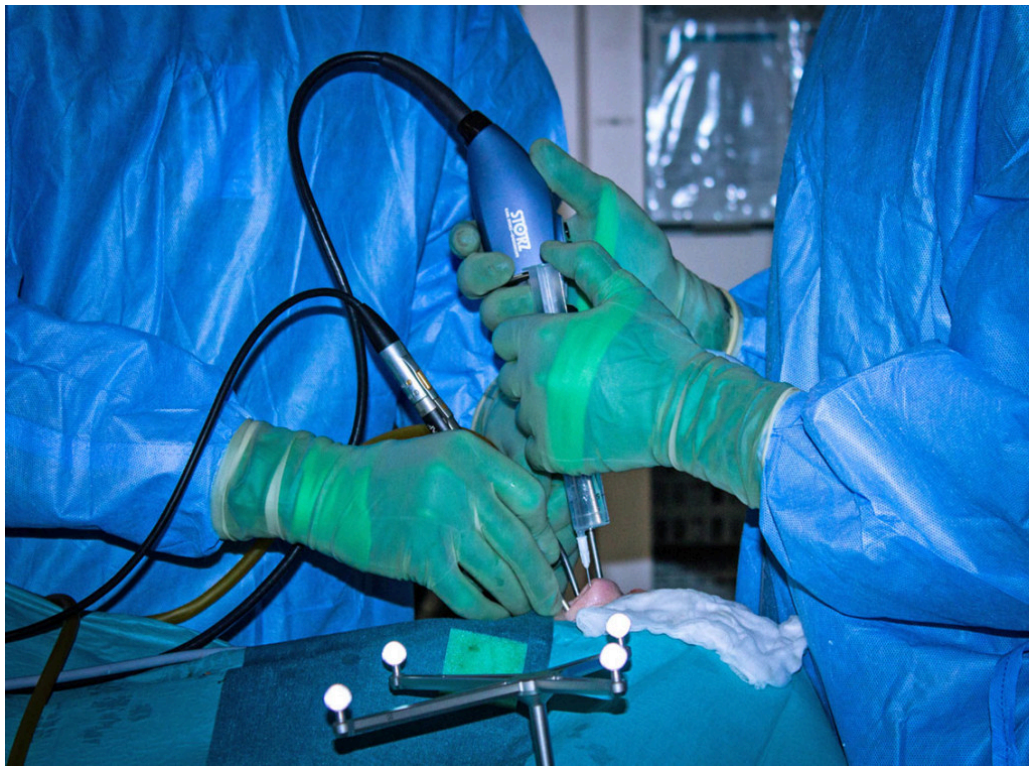

Figure 3 Endoscopic four-hands technique with two surgeons working together. One uses both hands to dissect, the other controls the endoscope and keeps the surgical field clear. Instrument manipulation must be well-coordinated between the surgeons.

Complications

The most common complications following surgery for tumours in the sellar region, irrespective of surgical technique, are associated with the visual system, pituitary gland and pituitary stalk, as well as the approach via the nose with opening in the skull base. Up to 30 % of patients develop transient syndrome of inappropriate antidiuretic hormone secretion (SIADH) 7–10 days postoperatively [\(8\)](#).

Endoscopic surgery does not result in greater hyponatraemia than microscopic pituitary surgery [\(9, 10\)](#). The same applies to the rate of cerebrospinal fluid (CSF) leak [\(9, 11\)](#). In a prospective multicentre study in the United States, which only included pituitary centres with high levels of expertise, the rate of CSF leak was 3.4 % for pituitary tumour surgery with an endoscopic four-hands technique compared to 4.9 % for microscopic surgery (non-significant difference) [\(10\)](#). At Oslo University Hospital, we have previously reported a CSF leak rate of 4.7 %, which remained unchanged after the introduction of the endoscopic four-hands technique [\(4\)](#).

Permanent complete or partial hypopituitarism is a known complication of and quality marker for pituitary tumour surgery. In surgical tumour resection, we endeavour to differentiate between normal pituitary tissue and tumour tissue, which is highly challenging. In a prospective multicentre study in the United States comparing an endoscopic four-hands technique with a microscopic technique, the endoscopic technique was clearly better in terms of the lower proportion of patients with new onset hypopituitarism at the six-month check-up (9.7 %, versus 28.4 % for the microsurgical technique ($p < 0.001$)) [\(10\)](#). The number of patients with hypopituitarism was also significantly lower in a meta-analysis that compared endoscopic surgery (not specified whether it was a two-hands or four-hands technique) with a microsurgical technique [\(9\)](#).

Extent of resection with surgery

The main objective of surgery for the vast majority of tumours in the pituitary region is complete tumour removal with the lowest possible risk of complications. This can lead to serious disease being cured in functional/hormone-producing tumours. Several studies and meta-analyses have compared an endoscopic technique with a microscopic technique, but without explicitly differentiating between two-hands or four-hands techniques. The extent of tumour resection was higher with an endoscopic technique in several studies and meta-analyses, particularly for more complex tumours [\(11–16\)](#), but similar in other studies [\(9, 10\)](#).

«The extent of tumour resection was higher with an endoscopic technique in several studies and meta-analyses, particularly for more complex tumours»

It is important to point out that the extent of tumour resection varies considerably between different centres, irrespective of surgical technique, and is highly dependent on surgical volumes and experience. For example, this is illustrated in a Danish study from the Department of Neurosurgery in Odense, which compared the results with microsurgery to those with endoscopic surgery using a four-hands technique. This study reported mean complete resection in the endoscopic surgery group of 39 % versus 22 % in the microsurgery group ($p = 0.001$). The extent of resection for non-hormone-producing pituitary tumours in the US multicentre study with only highly specialised surgeons was 84 % for the endoscopic four-hands technique and 80 % for the microsurgical technique ($p = 0.47$) [\(10\)](#).

Our recommendations

Pituitary tumours can generally be removed surgically with a high extent of resection with both microsurgical and endoscopic techniques, provided that appropriate expertise is available. However, the endoscopic technique is more atraumatic, with a lower probability of postoperative hypopituitarism [\(9, 10\)](#). Consideration should be given to resecting more complex tumours in the sellar region with an endoscopic four-hands technique at centres with high surgical volumes and expertise [\(12, 17, 18\)](#).

The patients mentioned in the video have given their consent for the video to be published.

REFERENCES

1. Ostrom QT, Cioffi G, Waite K et al. CBTRUS Statistical Report: Primary Brain and Other Central Nervous System Tumors Diagnosed in the United States in 2014-2018. *Neuro-oncol* 2021; 23 (Suppl 2): iii1–105. [PubMed] [CrossRef]
2. Castelnovo P, Pistochini A, Locatelli D. Different surgical approaches to the sellar region: focusing on the "two nostrils four hands technique". *Rhinology* 2006; 44: 2–7. [PubMed]
3. Cavallo LM, Somma T, Solari D et al. Endoscopic Endonasal Transsphenoidal Surgery: History and Evolution. *World Neurosurg* 2019; 127: 686–94. [PubMed][CrossRef]
4. Halvorsen H, Ramm-Pettersen J, Josefsen R et al. Surgical complications after transsphenoidal microscopic and endoscopic surgery for pituitary

- adenoma: a consecutive series of 506 procedures. *Acta Neurochir (Wien)* 2014; 156: 441–9. [PubMed][CrossRef]
5. Wiedmann M, Lashkarivand A, Berg-Johnsen J et al. How I do it: endoscopic endonasal resection of tuberculum sellae meningioma. *Acta Neurochir (Wien)* 2021; 163: 2193–7. [PubMed][CrossRef]
 6. Wang EW, Gardner PA, Zanation AM. International consensus statement on endoscopic skull-base surgery: executive summary. *Int Forum Allergy Rhinol* 2019; 9 (S3): S127–44. [PubMed][CrossRef]
 7. Martinez-Perez R, Requena LC, Carrau RL et al. Modern endoscopic skull base neurosurgery. *J Neurooncol* 2021; 151: 461–75. [PubMed][CrossRef]
 8. Perez-Vega C, Tripathi S, Domingo RA et al. Fluid Restriction After Transsphenoidal Surgery for the Prevention of Delayed Hyponatremia: A Systematic Review and Meta-Analysis. *Endocr Pract* 2021; 27: 966–72. [PubMed][CrossRef]
 9. Chen J, Liu H, Man S et al. Endoscopic vs. Microscopic Transsphenoidal Surgery for the Treatment of Pituitary Adenoma: A Meta-Analysis. *Front Surg* 2022; 8: 806855. [PubMed][CrossRef]
 10. Little AS, Kelly DF, White WL et al. Results of a prospective multicenter controlled study comparing surgical outcomes of microscopic versus fully endoscopic transsphenoidal surgery for nonfunctioning pituitary adenomas: the Transsphenoidal Extent of Resection (TRANSSPHER) Study. *J Neurosurg* 2019; 132: 1043–53. [PubMed][CrossRef]
 11. Guo S, Wang Z, Kang X et al. A Meta-Analysis of Endoscopic vs. Microscopic Transsphenoidal Surgery for Non-functioning and Functioning Pituitary Adenomas: Comparisons of Efficacy and Safety. *Front Neurol* 2021; 12: 614382. [PubMed][CrossRef]
 12. Dhandapani S, Singh H, Negm HM et al. Cavernous Sinus Invasion in Pituitary Adenomas: Systematic Review and Pooled Data Meta-Analysis of Radiologic Criteria and Comparison of Endoscopic and Microscopic Surgery. *World Neurosurg* 2016; 96: 36–46. [PubMed][CrossRef]
 13. Messerer M, De Battista JC, Raverot G et al. Evidence of improved surgical outcome following endoscopy for nonfunctioning pituitary adenoma removal. *Neurosurg Focus* 2011; 30: E11. [PubMed][CrossRef]
 14. Almutairi RD, Muskens IS, Cote DJ et al. Gross total resection of pituitary adenomas after endoscopic vs. microscopic transsphenoidal surgery: a meta-analysis. *Acta Neurochir (Wien)* 2018; 160: 1005–21. [PubMed][CrossRef]
 15. Gao Y, Zhong C, Wang Y et al. Endoscopic versus microscopic transsphenoidal pituitary adenoma surgery: a meta-analysis. *World J Surg Oncol* 2014; 12: 94. [PubMed][CrossRef]

16. Singh H, Essayed WI, Cohen-Gadol A et al. Resection of pituitary tumors: endoscopic versus microscopic. *J Neurooncol* 2016; 130: 309–17. [PubMed] [CrossRef]
 17. Cossu G, Jouanneau E, Cavallo LM et al. Surgical management of giant pituitary neuroendocrine tumors: Meta-analysis and consensus statement on behalf of the EANS skull base section. *Brain Spine* 2022; 2: 100878. [PubMed][CrossRef]
 18. Cusimano MD, Kan P, Nassiri F et al. Outcomes of surgically treated giant pituitary tumours. *Can J Neurol Sci* 2012; 39: 446–57. [PubMed][CrossRef]
-

Publisert: 22 June 2023. Tidsskr Nor Legeforen. DOI: 10.4045/tidsskr.22.0693

Received 30.10.2022, first revision submitted 15.1.2023, accepted 17.3.2023.

Copyright: © Tidsskriftet 2025 Downloaded from tidsskriftet.no 20 December 2025.