

---

# A woman in her fifties with trismus and muscle spasms

---

## EDUCATIONAL CASE REPORT

BJØRN CHRISTIAN OLSEN

E-mail: [olsenb@sthf.no](mailto:olsenb@sthf.no)

Department of Internal Medicine

Telemark Hospital Trust, Skien

Bjørn Christian Olsen is a specialty registrar in internal medicine.

The author has completed the ICMJE form and declares no conflicts of interest.

TORRE TAKSDAL STUBHAUG

Department of Microbiology

Vestfold Hospital Trust, Tønsberg

Tore Taksdal Stubhaug is a senior consultant.

The author has completed the ICMJE form and declares no conflicts of interest.

JACOB DAG BERILD

Department of Vaccine Preventable Diseases

Norwegian Institute of Public Health

Jacob Dag Berild is a specialty registrar in community medicine.

The author has completed the ICMJE form and declares no conflicts of interest.

---

**A woman sought medical attention at the Accident and Emergency Department with trismus and facial muscle spasms, and a serious condition that rarely occurs in Norway was suspected.**

*A woman in her fifties sought medical attention at the Accident and Emergency Department due to trismus and facial muscle spasms, and was acutely referred to the Department of Infectious Diseases. She had undergone*

tonsillectomy as a child and non-toxic goitre had been identified several years previously. She was otherwise generally healthy and was not taking any regular medication. Three to four days before hospitalisation, she had gradually developed stiffness and pain bilaterally in the jaw muscles, and two days later facial muscle spasms that were exacerbated by activity. She had felt unwell, with chills, lethargy and poor appetite. Upon admission, her blood pressure was 154/91 mm Hg, pulse 81 BPM, respiratory rate 18 breaths per minute and rectal temperature 37.7 °C. She reported generalised headache and a sensation of fasciculations in her neck, the lower left quadrant of her abdomen and her right calf and foot, as well as dull, burning, non-radiating chest pain bilaterally. She denied suffering from diarrhoea, vomiting, dyspnoea, palpitations or lower limb oedema. A clinical examination showed normal auscultation findings over the heart and lungs. Deep palpation revealed tenderness over the temporal muscle and the jaw bilaterally. She had a pale, moist oral mucosa and clinical trismus with a mouth opening of 2 cm. On the dorsal side of her left hand she had two marks measuring 1 mm in diameter as a result of an animal bite, with no clinical signs of infection. A neurologist was asked to examine her, and found increased tone in the masseter muscle bilaterally and muscle spasms in the forehead after use of the facial muscles. The results of the neurological examination were otherwise normal.

Blood tests showed leukocytes of  $6.3 \cdot 10^9/l$  (reference range  $3.5\text{--}10 \cdot 10^9/l$ ) and C-reactive protein less than 5 mg/l ( $< 5$  mg/l). Electrolytes, creatine kinase, metabolism and renal and liver function were all normal. Troponin I was 1 ng/l (0–47 ng/l), and an electrocardiogram showed sinus rhythm with no signs of acute ischaemia.

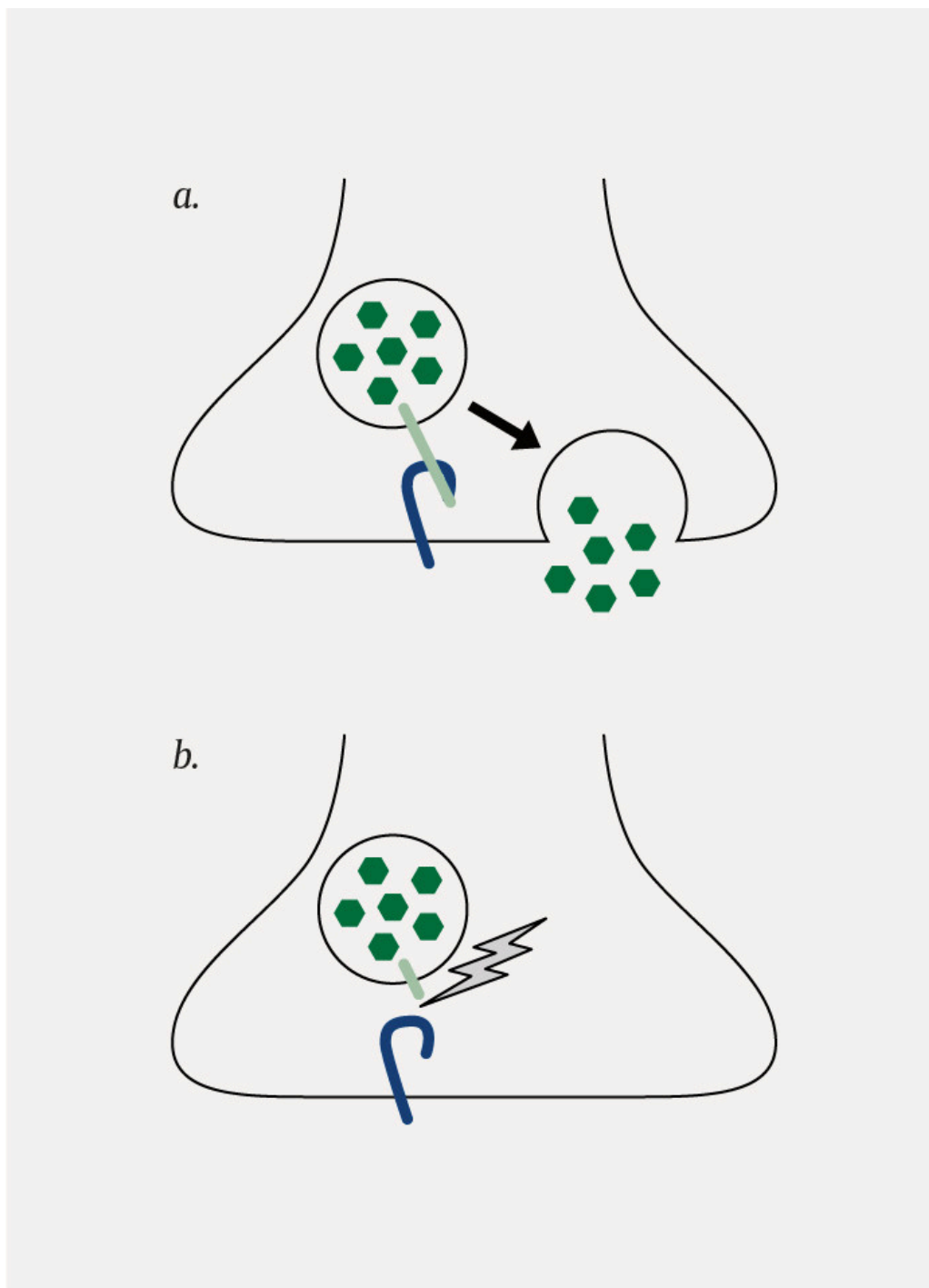
Findings of trismus and muscle spasms or cramps pose a number of differential diagnostic considerations. Hypocalcaemia may lead to muscle cramps and spasms, but our patient had normal electrolyte levels, including calcium. Odontogenic infections may result in trismus; however, our patient had normal oral mucosa and normal infection test results. Examination by an otorhinolaryngologist might have helped exclude a deeper odontogenic infection, but was not considered necessary upon admission. Meningitis and encephalitis may be associated with trismus and muscle spasms, but are often accompanied by symptoms such as headache, fever and altered mental status (1). A neurologist was consulted regarding indication for CT or MRI of the head, but since the patient had no neurological findings that pointed to a cerebral cause, this was not undertaken. Intoxication with neuroleptic drugs or rat poison containing strychnine may result in similar symptoms (2), but our patient denied having been in contact with such agents. The autoimmune disease stiff-person syndrome, with gradually increasing muscular rigidity and spasms was also a possible differential diagnosis, but this condition frequently starts with stiffness of the spine and neck, and trismus and facial symptoms are often absent in these patients (2).

According to the referring A&E doctor, the patient had been bitten on the left hand by a rabies-vaccinated cat in the United States three weeks prior to developing symptoms. The patient noticed that the bite wound had been red, tender and painful for a few days, but healed well with no visible infection.

*She had therefore not sought medical attention in the United States. Because of the animal bite and subsequent development of the symptoms in question, both the patient and the A&E doctor had begun to suspect tetanus. The patient had followed the vaccination programme as a child and been revaccinated for tetanus nine years previously. A few hours before admission she had been revaccinated with a tetanus-containing vaccine in the left deltoid muscle at a municipal vaccination centre.*

A diagnosis of tetanus is generally made on the basis of medical history and typical clinical findings [\(2\)](#). Tetanus is due to the toxic effect of tetanus neurotoxin, a protein that is produced by the anaerobic bacterium *Clostridium tetani*. It is seldom possible to obtain a microbiological culture as there are frequently few bacteria in the wound and the bacterium has a very low tolerance for oxygen during transport to the laboratory. Detecting *C. tetani* in tissue using PCR, or tetanus toxin in serum, can confirm the diagnosis, but these analyses are not available in Norway and their sensitivity is poorly documented. A low titer of tetanus immunoglobulin in serum may strengthen clinical suspicion. None of the tests mentioned can be used to exclude tetanus [\(2–4\)](#). Electromyography often shows normal findings or non-specific changes. Some studies have shown that detection of so-called 'silent periods' – periods of spinal inhibitory reflexes during normal muscle contraction that are recorded by electromyography – are absent in tetanus cases [\(5\)](#). In contrast to other neurological conditions, electroencephalography (EEG) shows normal findings in tetanus cases [\(2\)](#).

Tetanus neurotoxin functions as a protease and irreversibly cleaves vesicle-associated membrane protein (VAMP), a SNARE protein (soluble N-ethylmaleimide-sensitive factor attachment protein receptor) that is essential for the release of neurotransmitters from synaptic vesicles (Figure 1). The toxin migrates by retrograde axonal transport via motor neurons to inhibitory interneurons in the spinal cord, where it prevents the release of the inhibitory neurotransmitter *gamma*-aminobutyric acid (GABA). This leads to increased excitability in the postsynaptic neuron [\(6\)](#). The tetanus bacterium is spore-forming, and the spores are present in abundant quantities in nature, for example in soil and in the alimentary canal of animals and insects [\(2, 7\)](#). If the spores are inoculated into open wounds, they may germinate in necrotic tissue where the conditions are anaerobic, and produce toxin. The incubation period varies from 3 to 21 days [\(8\)](#).



**Figure 1** a) Release of neurotransmitters normally occurs through binding of vesicle-associated membrane protein (VAMP, shown in light green) with SNARE proteins (soluble N-ethylmaleimide-sensitive factor attachment protein receptor, shown in blue), which brings the synaptic vesicle into contact with the cell membrane. b) Tetanus neurotoxin cleaves VAMP and prevents the release of the neurotransmitter.

*In light of a relatively recent animal bite and clinical suspicion, the hospital physician made the decision to treat the patient for tetanus.*

Treatment of tetanus consists of neutralising circulating toxin by means of active and passive immunisation, eliminating toxin-producing bacteria with wound revision and antibiotics, reducing muscle cramps and providing supportive treatment. Tetanus toxin is neutralised by human tetanus immunoglobulin (HTIg). HTIg is only effective against free toxin and has no effect on toxin that is already bound to the neuronal synapses. HTIg is

preferably injected intramuscularly and should not be administered in the same area as a tetanus vaccine due to the risk of interactions [\(3, 9\)](#). Metronidazole is recommended in preference to penicillin in order to eliminate the toxin-producing bacteria, since penicillin is a GABA antagonist and may therefore exacerbate muscle spasms [\(2, 9\)](#). The recommended length of treatment for metronidazole is seven to ten days [\(9\)](#). Surgical revision of the assumed focus of infection should always be considered, but in our patient the bite wound had almost completely healed three weeks after the assumed infection date, and revision was therefore not undertaken.

*In consultation with the senior infectious disease control consultant at the Norwegian Institute of Public Health, it was decided to administer 3000 IU HTIg. Seven ampoules of 250 IU were available in the emergency department. The drug that is available in Norway is Tetagam 250 IU/ml. A further twelve ampoules were urgently ordered from Vitus Pharmacy Jernbanetorget, which safeguards 24-hour dispensing of rarely used immunoglobulins in collaboration with the Norwegian Institute of Public Health. While awaiting delivery from the pharmacy, all available HTIg, a total of 1750 IU, was administered five hours after admission, of which five ampoules by intramuscular injection: one in the gluteal muscle bilaterally, one in each thigh and one in the right deltoid muscle. The manufacturer recommends that doses of more than 5 ml should be injected in different locations. In addition, one ampule was injected subcutaneously on each side of the jaw. The injections were uncomplicated.*

*The patient was admitted to the Intensive Care Department for monitoring. When the ampoules arrived from the pharmacy later on the same day, a further 1250 IU HTIg was injected, so that the patient received a total of 3000 IU on the day of admission. Since HTIg has a half-life of three to four weeks, further injections were put on hold. Our patient received 500 mg metronidazole intravenously three times a day for ten days.*

The lethality of tetanus is reported to be as high as 60 %, and is often due to general muscle cramps and autonomic dysfunctions such as respiratory problems, tachycardia, hypotension and hyperthermia [\(2, 10\)](#).

Benzodiazepines, particularly diazepam, are the first choice of muscle relaxant, and patients with tetanus have been reported to tolerate and require high doses owing to general myoclonia [\(10\)](#). In a randomised study, magnesium sulphate infusion was found to reduce the need for other muscle relaxants and to reduce the effects of autonomic dysfunction [\(2\)](#). In patients with pronounced muscle cramps, propofol or a neuromuscular blocking agent may also be necessary. Pancuronium, vecuronium and doxacurium are reported to be the most widely used [\(2\)](#).

*The muscle cramps were alleviated with diazepam tablets. The woman had unobstructed respiration, stable circulation and subjectively improved trismus. She was therefore moved to a ward the day after her admission. During her stay she experienced prickling and discomfort in her abdomen, back and thighs which developed into muscular cramps in connection with physical activity, loud noise and light. The cramps were either focal or general, and lasted from several minutes to half an hour. Light-proofing of windows, double hearing protection and dark sunglasses supplemented the*

diazepam in alleviating the muscular symptoms. At times the patient experienced generalised, painful muscle cramps, and paracetamol and tapentadol had a beneficial effect. She was afebrile and her circulation and respiration were stable during her stay. She needed to lie still for much of the day, and therefore received thrombosis prophylaxis during her period in hospital.

Two weeks after admission, the cramps became milder and less frequent. The woman tolerated somewhat more light and sound, and her vital signs were still stable. She had no need for more HTIg injections. After four weeks she was able to lessen the window screening, and the cramps occurred still more rarely. The patient was discharged to her home with a tapering schedule for benzodiazepines. As the disease she had suffered does not confer immunity, the Norwegian Institute of Public Health recommended full revaccination one and six months after the first dose.

The woman came for follow-up at the Neurological Outpatients Clinic four months after her discharge. At times she still experienced painful cramps in the fingers and lower extremities. She was not troubled by trismus.

Neurography revealed almost normal motor and sensory findings in thick nerve fibres. Electromyography revealed no pathological spontaneous activity. Two months later she reported gradual improvement with fewer and less intense muscle spasms, but still used sunglasses and light-screening of windows indoors. Hard chewing caused stiffness of the jaw, and she experienced fatigue and an increased need for sleep. A year after discharge the patient was still improving gradually. She increasingly tolerated sound and light, but found that prolonged stimuli led to involuntary muscle spasms.

---

## Discussion

Our patient developed trismus and facial spasms three weeks after a cat bite. Clinical suspicion rapidly went to tetanus, and because of the seriousness of the diagnosis and absence of more probable differential diagnoses, she was treated on the grounds of clinical suspicion with human tetanus immunoglobulin, antibiotics and muscle relaxants.

Generalised tetanus is the most common form of clinical tetanus and may be caused by small, seemingly innocent wounds. In about 10 % of cases, the infection's access point in the skin or mucosa is never found, which may lead to the diagnosis being missed (2, 10). The condition involves several muscle groups, but onset often takes the form of intermittent muscle spasms and rigidity of the head, throat, thorax and abdomen. The incidence of trismus is reported to be 50–96 % (2, 9), but this, along with cramps of the back and neck muscles (opisthotonus), is often regarded as a classic symptom of tetanus. Persistent trismus leads to risus sardonicus (the sardonic smile) (11).

Our patient had a milder course of symptoms than previously published tetanus cases. This may be partly attributable to the fact that she had previously been vaccinated against tetanus, and that there was relatively little penetration of the skin at the bite site. A review article describes the development of symptoms in tetanus, with muscle cramps often predominating in the first

week, and autonomic dysfunction with hypotension, tachycardia, obstructed respiration and hyperthermia predominating in week two. As the effect of the tetanus toxin on the synapses is irreversible, clinical improvement cannot be expected until new nerve ends form after six–seven weeks (12). Tetanus myoclonia in the diaphragm, larynx and/or pharynx can develop rapidly and lead to compromised airways. Several studies therefore recommend that intubation and monitoring in the Intensive Care Department be considered at an early stage (2, 10, 12).

Tetanus vaccination was introduced into the Norwegian infant vaccination programme in 1952. The Norwegian Institute of Public Health recommends that non-immunocompromised people who have had primary vaccination be given a booster dose of tetanus vaccine in the event of wounds if it is more than ten years since the last vaccination for a clean wound, or more than five years for an unclean wound (3). Persons who have not had the primary vaccination course of three doses should start or complete the primary vaccination course. Unclean wounds are defined as wounds that are visibly contaminated or that are not cleaned or revised within six hours of the injury. Deep puncture wounds are also defined as unclean. In addition to vaccination, the Norwegian Institute of Public Health recommends injection of 250 IU HTIg as prophylactic treatment for unclean wounds that are not fully revised within six hours, in persons who have not undergone primary vaccination (3).

Our patient had undergone primary vaccination and been revaccinated nine years before the onset of symptoms. A cross-sectional study of 546 adults from 2016 found that anti-tetanus toxoid titer had a half-life of 14 years after vaccination, and forecasts that 95 % of the population will be protected for more than 30 years after primary vaccination (13). However, cat bites are often deep, and the bowels of animals, including cats, often contain *C. tetani* (2, 7). This indicates that animal bites, and cat bites in particular, should also be classified as unclean wounds, irrespective of the appearance of the wound, unless the wound is adequately revised within six hours of the injury.

---

*The patient has consented to the publication of the article.*

*The authors thank the patient for her positive cooperation during the work on the manuscript.*

*The article has been peer-reviewed.*

---

## LITERATURE

1. Weinstein L. Tetanus. N Engl J Med 1973; 289: 1293–6. [PubMed] [CrossRef]
2. Brook I. Current concepts in the management of Clostridium tetani infection. Expert Rev Anti Infect Ther 2008; 6: 327–36. [PubMed][CrossRef]
3. Folkehelseinstituttet. Tetanusvaksine (stivkrampe) og tetanusimmunglobulin – veileder for helsepersonell. <https://www.fhi.no/nettpub/vaksinasjonsveilederen-for->

helsepersonell/vaksiner-mot-de-enkelte-sykdommene/tetanusvaksinasjon-stivkrampe-ogte/ Read 2.2.2019.

4. Crone NE, Reder AT. Severe tetanus in immunized patients with high anti-tetanus titers. *Neurology* 1992; 42: 761–4. [PubMed][CrossRef]
  5. Srinivasan J, Sabin TD. Tetanus. In: Katirji B, Kaminski HJ, Ruff RL, red. *Neuromuscular disorders in clinical practice*. New York, NY: Springer Science and Business Media, 2014: 1444.
  6. Montecucco C, Rossetto O, Popoff MR. Neurotoxicogenic Clostridia. In: Dworkin M, Falkow S, Rosenberg E et al., eds. *Bacteria: Firmicutes, Cyanobacteria*. New York, NY: Springer US; 2006: 679–97. (Vol. 4 of the series: Dworkin M, Falkow S, Rosenberg E et al., eds. *The Prokaryotes: a handbook on the biology of bacteria*. 4th ed.)
  7. Wiegel J, Tanner R, Rainey FA. An Introduction to the Family Clostridiaceae. In: Dworkin M, Falkow S, Rosenberg E, et al., eds. *Bacteria: Firmicutes, Cyanobacteria*. New York, NY: Springer US; 2006: 679–97. (Vol. 4 of the series: Dworkin M, Falkow S, Rosenberg E, et al., ed. *The Prokaryotes: a handbook on the biology of bacteria*. 4th ed.)
  8. Folkehelseinstituttet. Tetanus (stivkrampe) – veileder for helsepersonell. <https://www.fhi.no/nettpub/smittevernveilederen/sykdommer-a-a/tetanus-stivkrampe---veileder-for-h/> Read 2.2.2019.
  9. Farrar JJ, Yen LM, Cook T et al. Tetanus. *J Neurol Neurosurg Psychiatry* 2000; 69: 292–301. [PubMed][CrossRef]
  10. Ergonul O, Egeli D, Kahyaoglu B et al. An unexpected tetanus case. *Lancet Infect Dis* 2016; 16: 746–52. [PubMed][CrossRef]
  11. Pihlstrøm L. Det sardoniske smil. *Tidsskr Nor Legeforen* 2011; 131: 2500–3. [PubMed][CrossRef]
  12. Gibson K, Bonaventure Uwineza J, Kiviri W et al. Tetanus in developing countries: a case series and review. *Can J Anaesth* 2009; 56: 307–15. [PubMed][CrossRef]
  13. Hammarlund E, Thomas A, Poore EA et al. Durability of vaccine-induced immunity against tetanus and diphtheria toxins: A crosssectional analysis. *Clin Infect Dis* 2016; 62: 1111–8. [PubMed][CrossRef]
- 

Publisert: 30 October 2019. *Tidsskr Nor Legeforen*. DOI: 10.4045/tidsskr.18.0987

Received 29.12.2018, first revision submitted 18.4.2019, accepted 16.9.2019.

© Tidsskrift for Den norske legeforening 2025. Downloaded from tidsskriftet.no 27 December 2025.