

---

# Visual dysfunction in multiple sclerosis

---

## CLINICAL REVIEW

JANA MIDELFART HOFF

E-mail: [jana.midelfart.hoff@helse-bergen.no](mailto:jana.midelfart.hoff@helse-bergen.no)

Department of Neurology

and

Norwegian Multiple Sclerosis Competence Centre

Haukeland University Hospital

She has contributed to the study concept, data collection and interpretation, literature review, and to the drafting and revision of the manuscript.

Jana Midelfart Hoff, dr.med., senior consultant with an interest in neurology and vision acquired through many years of clinical experience with MS patients.

The author has completed the ICMJE form and declares no conflicts of interest.

MAURAN DHAYALAN

Department of Clinical Medicine

University of Bergen

He has contributed to data collection, literature review, and to the drafting and revision of the manuscript.

Mauran Dhayalan, cand.med., has written an undergraduate thesis on the topic.

The author has completed the ICMJE form and declares no conflicts of interest.

ANNA MIDELFART

Department of Neuromedicine and Movement Science

Faculty of Medicine and Health Sciences

NTNU

She has contributed to data collection and interpretation, literature review, and to the drafting and revision of the manuscript.

Anna Midelfart is a specialist in ophthalmology, professor emerita and neuro-ophthalmologist with a particular interest in the intersection between vision and neurology.

The author has completed the ICMJE form and declares no conflicts of interest.

ANE ROUSHAN THARALDSEN

Department of Ophthalmology  
Stavanger University Hospital

She has contributed to data collection and interpretation, literature review, and to the drafting and revision of the manuscript.

Ane Roushan Tharaldsen is a senior consultant specialising in ophthalmology, and conducts research into visual impairments after stroke.

The author has completed the ICMJE form and declares no conflicts of interest.

LARS BØ

Department of Neurology  
Haukeland University Hospital  
and

Department of Clinical Medicine  
University of Bergen  
and

Norwegian Multiple Sclerosis Competence Centre  
Haukeland University Hospital

He has contributed to the study concept, data collection and interpretation, literature review, and to the drafting and revision of the manuscript.

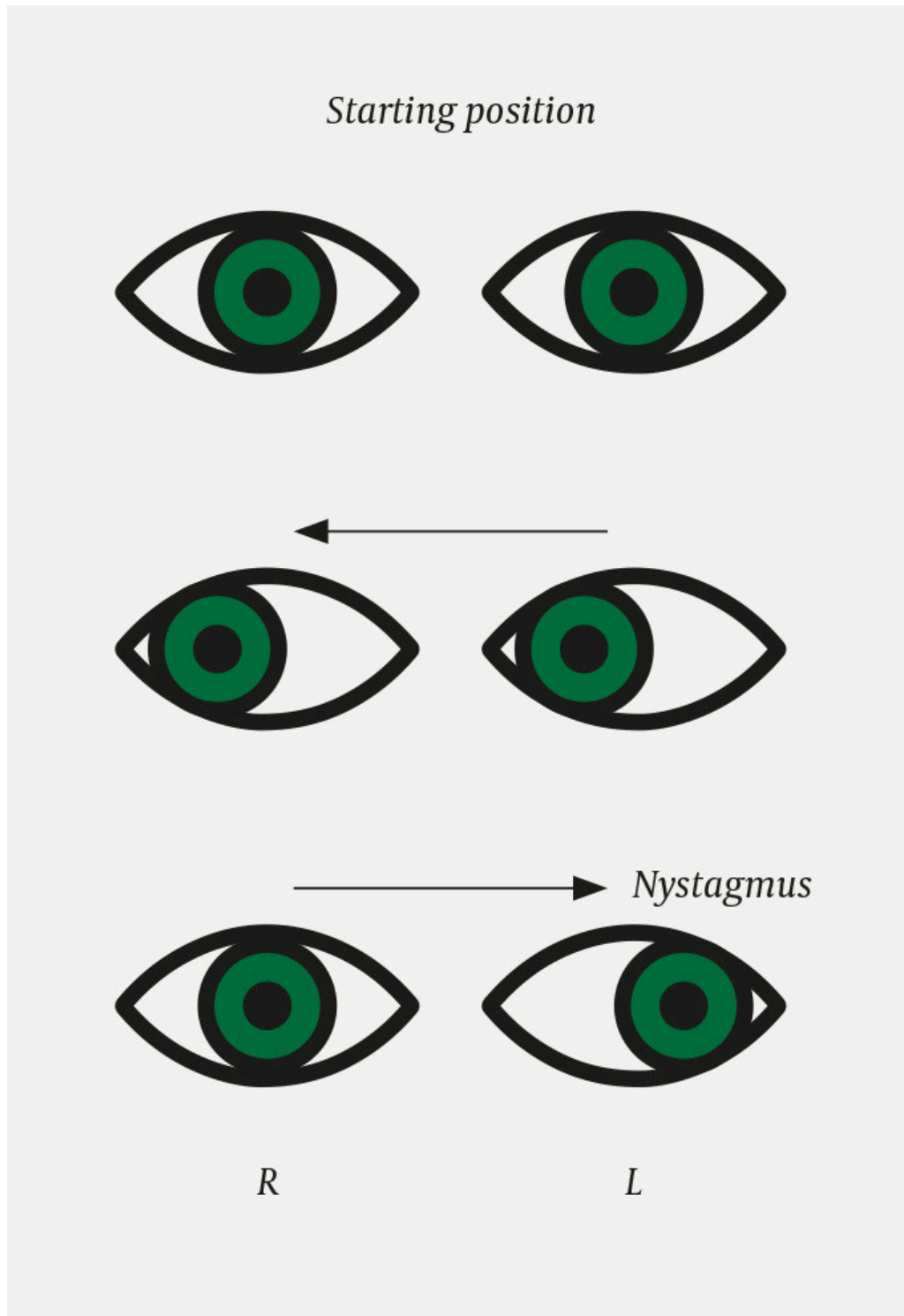
Lars Bø, professor and director of the Norwegian Multiple Sclerosis Competence Centre. He has many years of experience of working with patients with MS, both in clinical practice and research.

The author has completed the ICMJE form and declares the following conflicts of interest: He has received fees from the law firm Kvale for providing expert opinions, and lecture fees from Biogen and Genzyme.

---

**Multiple sclerosis can give rise to signs and symptoms from the entire nervous system, including visual impairments. Visual impairments often go unreported because they are not obvious to patients, which means that doctors must ask about them specifically. Regular monitoring of vision is**

important, however, to provide personalised rehabilitation and assistive technologies, and thereby improve patients' functioning and quality of life.



**Figure 1** Internuclear ophthalmoplegia

Multiple sclerosis (MS) is a neurological disorder characterised by inflammation, demyelination and neurodegeneration of the central nervous system [\(1\)](#). The prevalence in Norway is among the highest in the world, with 208 cases per 100 000 population [\(2\)](#). Visual dysfunction occurs frequently in patients with MS. In a review conducted by the North American Research Committee on Multiple Sclerosis, 60 % of 9 107 patients reported visual

impairments. Of these, 14 % had moderate/severe/very severe impairment of visual function (3). Visual dysfunction may take the form of reduced visual acuity and altered colour vision, as in cases of optic neuritis, or ocular motility disorders caused by disruption of interactions between various parts of the central nervous system. Some MS medications can also affect visual function.

This article is based on a discretionary selection of reviews and original articles, as well as the authors' clinical experience with this patient population.

---

## Most common visual disturbances

### Acute optic neuritis

Optic neuritis – inflammation of the optic nerve – often occurs in association with multiple sclerosis or neuromyelitis optica. It can also be caused by infections and other immunological conditions.

Typical signs and symptoms of acute optic neuritis are a subacute course with unilateral vision loss, pain upon eye movement, altered pupillary light reflex, and altered colour vision. The loss of vision typically develops over hours to days and can vary from slightly reduced visual acuity to loss of the ability to detect light; however, a central visual field defect is often present in the affected eye. Inflammation of the optic nerve is the first symptom of multiple sclerosis in 20 % of patients (4, 5). For multiple sclerosis to be diagnosed, there must be objective evidence of disease activity in the central nervous system that is disseminated in time (one or more relapses, MRI lesions, or detection of oligoclonal bands in cerebrospinal fluid) and space (MRI lesions or clinical relapses) (6).

An American cohort study followed up patients with acute unilateral optic neuritis who did not meet the criteria for MS. After 15 years, half of the patients had received an MS diagnosis. The risk of developing multiple sclerosis was greatest in the first five years (7).

Acute optic neuritis in multiple sclerosis is often self-limiting. Almost all patients experience an improvement in visual function within three weeks, although some have long-term symptoms. It has been suggested that a specific questionnaire with questions on visual impairments should be used in patients with MS (8, 9). In addition to visual acuity, patients should be tested for colour vision with Ishihara's test and for contrast sensitivity. Altered contrast sensitivity affects quality of vision, especially face recognition, reading and activities of daily living (10).

### Ocular motility disorders

Damage to nerve fibres from nuclei in the brainstem and cerebellum can lead to ocular motility disorders. Whereas near full recovery is common after acute optic neuritis, ocular motility disorders often cause persistent ocular symptoms such as diplopia (11).

A common form of ocular motility disorder in MS is internuclear ophthalmoplegia, which is estimated to affect more than 20 % of patients (12). Among 70 patients with MS who had persistent visual impairments, 59 were found to have an ocular motility disorder (84.3 %). Of these, 39 (55.7 %) had internuclear ophthalmoplegia, which was bilateral in 22 (31.4 %) cases (13). Internuclear ophthalmoplegia results from dysfunction of the medial longitudinal fasciculus in the brainstem: disruption of the pathway between an abducens nucleus and the contralateral oculomotor nucleus (the medial longitudinal fasciculus) gives rise to a dysconjugate lateral gaze. Internuclear ophthalmoplegia can be detected clinically by asking the patient to look to the left and to the right in the horizontal plane. The adduction of one eye (ipsilesional) will then be slow or impaired, while the abducting eye (contralesional) displays horizontal nystagmus (14). Convergence is usually preserved; its disruption would suggest a more extensive lesion (15). Internuclear ophthalmoplegia may be either unilateral or bilateral (13).

The medial longitudinal fasciculus is a predilection site in the brainstem for MS lesions. Besides multiple sclerosis, internuclear ophthalmoplegia may also be caused by vascular, infectious, traumatic and neoplastic conditions.

### **Isolated cranial nerve palsies and gaze palsies**

MS is rarely the cause of isolated cranial nerve palsies, but they are sometimes seen upon disease onset or during relapses (16). Especially in younger patients, it is important to consider MS as a possible cause. The main symptom is diplopia, and the abducens and oculomotor nerves are the most commonly affected. Trochlear nerve palsy is almost never seen.

MS lesions in the brainstem can lead to serious visual disturbances with horizontal gaze palsy, but are relatively rare. In such cases, patients will be unable to move their eyes in the horizontal plane (to one or both sides) (17).

### **Abnormalities of visual fixation and nystagmus**

Saccadic dysfunction and nystagmus are fairly common in patients with MS. They are caused by demyelination of the cerebellum or of tracts between the cerebellum and brainstem (18).

Saccades are rapid eye movements where the eyes shift focus from one object to another with a smooth, flowing and synchronous movement. Nystagmus refers to involuntary, rhythmic eye movements in association with a reduced ability to maintain fixation. When examining saccadic eye movements, the patient is asked to shift his or her gaze to the side from one object to another (Box 1). In saccadic dysmetria, the patient's gaze overshoots or undershoots the target object. The patient's eyes typically make corrective movements back and forth before finally managing to fixate the object.

---

### **Box 1 Characterisation of saccades and nystagmus**

#### **SACCADES**

- Rapid eye movements

- Normal findings: Both eyes move in the same direction and shift focus from one object to another with a smooth, flowing and synchronous movement
- Saccades are tested by examining whether the patient can shift his or her gaze to the side from one object to another
- Saccadic dysmetria: The patient's gaze overshoots or undershoots the target object
- The patient's eyes can typically be seen to make corrective movements back and forth before finally managing to fixate the object

#### NYSTAGMUS

- Involuntary, rhythmic eye movements
  - Arises in association with a reduced ability to maintain fixation
  - Often detected while testing slow tracking movements of the eyes
  - Slow tracking movements can be tested by asking the patient to track an object in different directions with their eyes
  - Pathological, jerky adjustments
- 

Saccadic intrusions are disruptive eye movements that arise when a patient attempts to focus on an object. Several types occur in patients with MS: square wave jerks, opsoclonus and ocular flutter (17). 'Square wave jerks' are jerky movements back and forth, with an interval between each movement. Opsoclonus refers to high frequency conjugated eye movements of large and varying amplitude, but is very rarely seen in MS. Ocular flutter refers to small, high frequency eye movements in the horizontal plane (11).

Up to one in five patients with MS experiences pathological nystagmus (17). It may occur when the eyes are in a central position or when the gaze is moved in a particular direction. The most common form in MS is gaze-evoked nystagmus. This can be detected by testing slow tracking movements. The patient is asked to follow an object with their gaze in different directions, and pathological, jerky corrective movements can then be seen. Other patients with MS have pendular nystagmus where the movement of the eyes resembles a pendulum. This can often be disabling if it persists when the patient looks straight ahead. The world appears to 'quiver' (18). Vertical nystagmus, in which the eyes move up and down, is another form of nystagmus that may be seen in some patients with MS even when they look straight ahead (Box 1).

### Medication-induced visual disturbances

In May 2017, new Norwegian guidelines were published for the treatment of multiple sclerosis. The guidelines recommend that patients with relapsing-remitting multiple sclerosis should receive disease-modifying treatment without delay (6). However, some of these disease-modifying drugs may affect visual function. The best known is fingolimod, a drug that blocks the ability of lymphocytes to leave the lymph nodes, and which has macular oedema as an adverse effect (albeit uncommon). Macular oedema presents as metamorphopsia (in which wavy lines are seen when looking at a grid of straight lines) and gives rise to visual impairment. According to the Norwegian

guidelines, all patients who are treated with fingolimod should be examined by an ophthalmologist four months after treatment initiation [\(6\)](#). Patients with diabetes mellitus or a history of uveitis are at increased risk of macular oedema, and should receive an ophthalmological examination prior to starting treatment [\(6\)](#).

Natalizumab, another potent immunosuppressant, may also affect vision. Approximately 4 out of 1 000 patients treated with natalizumab will develop progressive multifocal leukoencephalopathy (PML) caused by the JC virus. Risk is dependent on whether a patient is positive for antibodies against the JC virus. Progressive multifocal leukoencephalopathy is potentially life-threatening, and in 1 in 4 patients it manifests with hemianoptic visual field loss [\(19\)](#). All patients with MS should be screened for JC virus prior to starting natalizumab and should then be checked periodically for antibodies [\(19\)](#). Cases of acute retinal necrosis have also been reported in patients on natalizumab, with a high risk of severe vision loss [\(20\)](#).

---

## Examination and treatment

Patients with visual dysfunction should be referred for ophthalmological assessment of ocular motility, visual acuity and colour vision, as well as perimetry testing to measure their visual field [\(21\)](#). Structural measurements with optical coherence tomography (OCT) have been shown to be very useful in the diagnosis and follow-up of optic neuritis; thinning of the retinal nerve fibre layer indicates axonal damage [\(22\)](#).

Reduced colour vision, which affects many patients with MS – even those without previously diagnosed optic neuritis – is correlated with reduction of the retinal nerve fibre layer [\(23\)](#). Electrophysiological assessment of visual evoked potentials (VEPs) may reveal reduced nerve conduction velocity in patients with a history of optic neuritis. The use of prisms to reduce symptoms may be appropriate in some types of nystagmus or in cases of minor paresis. More severe cases of paresis may be treated with Botox injections or strabismus surgery. Short-term occlusion therapy may be used in cases of diplopia, and certain medications may help with ocular motility disorders [\(9\)](#). Dependent on findings, the patient may be referred for personalised follow-up and training by a specialist in visual pedagogy.

---

## Quality of life

Visual dysfunction means that many patients with MS have a reduced ability to drive, use a computer/mobile phone or watch television. Other common difficulties include problems focusing on moving objects, as well as cloudy vision and 'tired eyes'. Patients with MS describe significantly reduced quality of life in association with altered visual function [\(24\)](#). This may be because even a minor visual impairment can have a substantial impact on those who already have motor, sensory and/or coordination difficulties.



---

## Conclusion

Visual dysfunction is common in patients with MS. The most common conditions are acute optic neuritis, internuclear ophthalmoplegia, nystagmus and saccadic dysmetria. Many patients with MS describe vision as important for their quality of life, and experience a reduced quality of life because of reduced visual function. The degree of visual impairment can be determined by asking patients with MS specific questions about whether they experience problems with using a mobile phone, computer or TV, with reading or during physical or outdoor activities. Questions about difficulty participating in social activities will identify further patients in need of assistance. Personalised interventions and targeted rehabilitation and assistive technologies have the capacity to improve patients' quality of life.

---

*This article has been peer-reviewed.*

---

## LITERATURE

1. Olek MJ, Mowry E. Pathogenesis and epidemiology of multiple sclerosis. UpToDate versjon 12.0, 2016.  
<https://www.uptodate.com/contents/pathogenesis-and-epidemiology-of-multiple-sclerosis> Lest 7.1.2017.
2. Grytten N, Torkildsen Ø, Myhr KM. Time trends in the incidence and prevalence of multiple sclerosis in Norway during eight decades. *Acta Neurol Scand* 2015; 132: 29–36. [PubMed][CrossRef]
3. Salter AR, Tyry T, Vollmer T et al. "Seeing" in NARCOMS: a look at vision-related quality of life in the NARCOMS registry. *Mult Scler* 2013; 19: 953–60. [PubMed][CrossRef]
4. Burman J, Raininko R, Fagius J. Bilateral and recurrent optic neuritis in multiple sclerosis. *Acta Neurol Scand* 2011; 123: 207–10. [PubMed][CrossRef]
5. Sørensen TL, Frederiksen JL, Brønnum-Hansen H et al. Optic neuritis as onset manifestation of multiple sclerosis: a nationwide, long-term survey. *Neurology* 1999; 53: 473–8. [PubMed][CrossRef]
6. Helsedirektoratet. Nasjonal faglig retningslinje for diagnostikk, attack og sykdomsmodulerende behandling av multipel sklerose.  
<https://www.helsedirektoratet.no/retningslinjer/multipel-sklerose> Lest 30.5.2017.
7. Optic Neuritis Study Group. Multiple sclerosis risk after optic neuritis: final optic neuritis treatment trial follow-up. *Arch Neurol* 2008; 65: 727–32. [PubMed]



8. Ma SL, Shea JA, Galetta SL et al. Self-reported visual dysfunction in multiple sclerosis: new data from the VFQ-25 and development of an MS-specific vision questionnaire. *Am J Ophthalmol* 2002; 133: 686–92. [PubMed][CrossRef]
9. Hickman SJ, Raoof N, McLean RJ et al. Vision and multiple sclerosis. *Mult Scler Relat Disord* 2014; 3: 3–16. [PubMed][CrossRef]
10. Leat SJ, Legge GE, Bullimore MA. What is low vision? A re-evaluation of definitions. *Optom Vis Sci* 1999; 76: 198–211. [PubMed][CrossRef]
11. Biousse V, Newman NJ. *Neuro-Ophthalmology Illustrated*. New York, NY: Thieme Medical Publishers, 2015.
12. Feroze KB, Wang J. Internuclear ophthalmoplegia. *StatPearls*. <https://www.ncbi.nlm.nih.gov/books/NBK441970/> Lest 7.1.2017.
13. Jasse L, Vukusic S, Durand-Dubief F et al. Persistent visual impairment in multiple sclerosis: prevalence, mechanisms and resulting disability. *Mult Scler* 2013; 19: 1618–26. [PubMed][CrossRef]
14. Brautaset NJ. Internuclear ophthalmoplegia. *Tidsskr Nor Lægeforen* 2010; 130: 2124. [PubMed][CrossRef]
15. Subei AM, Eggenberger E. Efferent manifestations of multiple sclerosis. *Curr Opin Ophthalmol* 2012; 23: 506–9. [PubMed][CrossRef]
16. Barr D, Kupersmith MJ, Turbin R et al. Isolated sixth nerve palsy: an uncommon presenting sign of multiple sclerosis. *J Neurol* 2000; 247: 701–4. [PubMed][CrossRef]
17. Barnes D, McDonald WI. The ocular manifestations of multiple sclerosis. 2. Abnormalities of eye movements. *J Neurol Neurosurg Psychiatry* 1992; 55: 863–8. [PubMed][CrossRef]
18. Nerrant E, Tilikete C. Ocular motor manifestations of multiple sclerosis. *J Neuroophthalmol* 2017; 37: 332–40. [PubMed][CrossRef]
19. Baldwin KJ, Hogg JP. Progressive multifocal leukoencephalopathy in patients with multiple sclerosis. *Curr Opin Neurol* 2013; 26: 318–23. [PubMed][CrossRef]
20. Sood AB, Kumar G, Robinson J. Bilateral acute retinal necrosis in a patient with multiple sclerosis on natalizumab. *J Ophthalmic Inflamm Infect* 2016; 6: 26. [PubMed][CrossRef]
21. Kerty E, Eide N, Nakstad P. Affeksjon av det visuelle system ved multipel sklerose. *Tidsskr Nor Lægeforen* 1993; 113: 1574–6. [PubMed]
22. Kupersmith MJ, Mandel G, Anderson S et al. Baseline, one and three month changes in the peripapillary retinal nerve fiber layer in acute optic neuritis: relation to baseline vision and MRI. *J Neurol Sci* 2011; 308: 117–23. [PubMed][CrossRef]

23. Felgueiras H, Parra J, Cruz S et al. Dyschromatopsia in multiple sclerosis patients: a marker of subclinical involvement? *J Neuroophthalmol* 2016; 36: 275–9. [PubMed][CrossRef]

24. Noble J, Forooghian F, Sproule M et al. Utility of the National Eye Institute VFQ-25 questionnaire in a heterogeneous group of multiple sclerosis patients. *Am J Ophthalmol* 2006; 142: 464–8. [PubMed][CrossRef]

---

Publisert: 2 August 2019. Tidsskr Nor Legeforen. DOI: 10.4045/tidsskr.18.0786

Received 8.10.2018, first revision submitted 29.3.2019, accepted 15.5.2019.

© Tidsskrift for Den norske legeforening 2025. Downloaded from tidsskriftet.no 21 December 2025.