
A foreign body in the urinary bladder

IMAGES IN MEDICINE

CLAUS KLINGENBERG

E-mail: claus.klingenberg@unn.no

Division of Child and Adolescent Health, University Hospital of North Norway

Department of Clinical Medicine, University of Tromsø – The Arctic University of Norway

Claus Klingenberg, MD, PhD, specialist in paediatric medicine, senior consultant and professor.

The author has completed the ICMJE form and reports no conflicts of interest.

THORSTEN KOEHLER

Department of Radiology, University Hospital of North Norway

Thorsten Koehler, specialist in radiology and senior consultant.

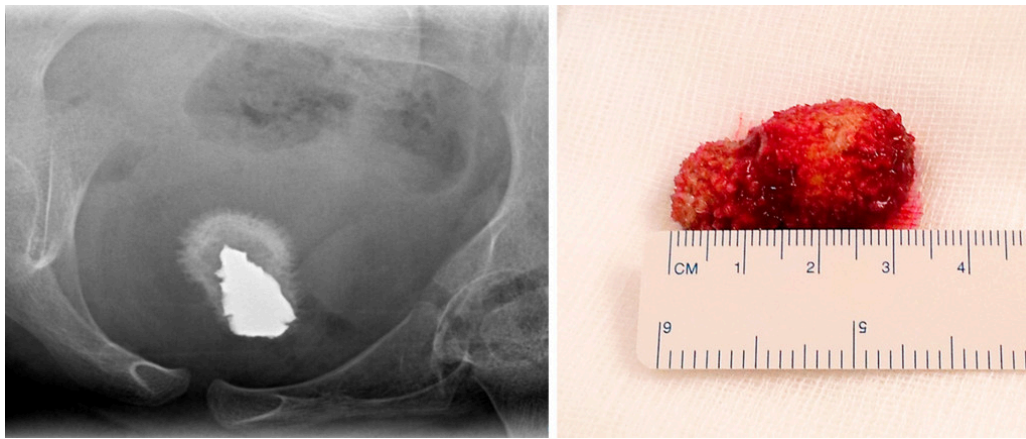
The author has completed the ICMJE form and reports no conflicts of interest.

JAN DUE

Jan Due, retired specialist in general surgery and urology. He was previously a senior consultant at the University Hospital of North Norway and associate professor at University of Tromsø – The Arctic University of Norway.

The author has completed the ICMJE form and reports no conflicts of interest.

Foreign bodies in the urinary bladder are generally introduced via the urethra, through a puncture or migration from neighbouring organs. It is essential to consider foreign bodies in the urinary bladder as a rare cause of pain and inflammation in the bladder region [\(1, 2\)](#).



A boy of primary school age from an African country was referred to the paediatric outpatient clinic soon after his arrival in Norway. It emerged that two years previously, he had been seriously injured by a bomb explosion in his home country. Following this accident, he had severe pain when urinating and passing stools. He was unable to lie on his back and generally slept sitting up. According to his father, an ultrasound examination had detected 'bladder stones' in the boy as a refugee in a neighbouring African country, but he had not received treatment.

Examination revealed the boy to be in good general condition. A star-shaped scar was visible behind his left thigh, but there was no scar on the abdomen or perineum. He reported pain when supine, but his abdomen was soft. Ultrasound showed a foreign body at the base of the bladder. Pelvic x-ray examination led to suspicion of a large metal fragment in the bladder (image on left).

The patient underwent a cystotomy, where a 3.5×2 cm large, yellow-coloured foreign body was found that proved to be a metal splinter covered in coral-like calcification (image on right). Most likely, the splinter had entered the bladder as a projectile via the entry point behind the left thigh (2).

The postoperative course was uncomplicated. The patient's pain when urinating receded immediately after the surgery, and he was able to sleep lying down.

The patient's parents have consented to the publication of this article.

LITERATURE

1. Mannan A, Anwar S, Qayyum A et al. Foreign bodies in the urinary bladder and their management: a Pakistani experience. *Singapore Med J* 2011; 52: 24–8. [PubMed]
 2. Kuy S, Somberg LB, Paul J et al. Undetected penetrating bladder injuries presenting as a spontaneously expelled bullet during voiding: a rare entity and review of the literature. *J Emerg Med* 2013; 45: e59–62. [PubMed] [CrossRef]
-

Publisert: 28 January 2019. Tidsskr Nor Legeforen. DOI: 10.4045/tidsskr.18.0324

