
A woman in her thirties with severe headache

EDUCATIONAL CASE REPORT

MARIANNE BOLLESTAD

E-mail: marianne.bollestad@medisin.uio.no

Department of Infectious Diseases

Division of Medicine

Stavanger University Hospital

and

The Antibiotic Centre of Primary Care

She has contributed with the idea for the manuscript, gathered information from medical records, conducted literature searches, prepared a draft, revised the manuscript and approved the final version. Marianne Bollestad (born 1981), specialty registrar in infectious diseases and doctoral research fellow.

The author has completed the ICMJE form and reports no conflicts of interest.

ÅSE BERG

Department of Infectious Diseases

Division of Medicine

Stavanger University Hospital

She has contributed with the idea for the manuscript, drafting and revision of the manuscript, and has approved the final version.

Åse Berg (born 1957), PhD, and senior consultant specialising in infectious diseases and internal medicine.

The author has completed the ICMJE form and reports no conflicts of interest.

MATIAS MATHISEN RAKE

Neurocentre

Stavanger University Hospital

He has contributed with literature searches, revision of the manuscript, and has approved the final version.

Matias Mathisen Rake (born 1986), specialty registrar.

The author has completed the ICMJE form and reports no conflicts of interest.

SUSANNE GJERULDSSEN DUDMAN

Department of Vaccine Preventable Diseases

Norwegian Institute of Public Health

She has contributed to the drafting and revision of the manuscript, including preparation of figures/tables, and has approved the final version.

Susanne Gjeruldsen Dudman (born 1964), MD PhD, specialist in medical microbiology and internal medicine. She is a senior consultant in charge of the national reference laboratory for polio-entero-rotavirus and the measles, mumps and rubella (MMR) vaccine.

The author has completed the ICMJE form and reports no conflicts of interest.

DAGNY HAUG DORENBERG

Department of Influenza

Norwegian Institute of Public Health

She has contributed to the drafting and revision of the manuscript, literature searches, and has approved the final version.

Dagny Haug Dorenberg (born 1966), specialist in internal medicine, infectious diseases, and medical microbiology. She is a senior consultant in charge of emergency preparedness for imported viruses.

The author has completed the ICMJE form and reports no conflicts of interest.

One week after a trip to Sri Lanka, a woman developed neck pain, headache and altered consciousness. Interdisciplinary collaboration proved vital for clarifying the diagnosis.

A woman in her thirties was referred by her general practitioner to the neurological department as an emergency case owing to a gradually worsening headache one week after returning from a three-week holiday in Sri Lanka. The patient was originally from Sri Lanka, but had lived in Norway for the past three years. She had previously been in good health, apart from occasional headaches.

Upon examination in Acute Admissions, the patient described neck pain radiating to the head, most pronounced frontally. The pain was intense and intermittent, with a sensation of pressure, and was accompanied by nausea and vomiting. The patient was notably in pain, but was awake and alert and

cooperated well with the examination. She was not photophobic and had no neck stiffness. Her blood pressure was 130/78 mm Hg, pulse 81 and temperature 37° C. Normal findings were obtained upon auscultation of the heart and lungs, and examination of the abdomen. Palpation revealed soreness, especially in the neck muscles and right occipital region. A preliminary neurological examination showed normal cranial nerves, strength, reflexes, sensory function and coordination. Consciousness was normal with a score of 15 on the Glasgow Coma Scale (GCS). Blood tests revealed haemoglobin 14.2 g/l (11.7–15.3), leukocytes $7.2 \cdot 10^9/l$ (3.5–8.8), thrombocytes $259 \cdot 10^9/l$ (165–387), CRP < 1 mg/l (0–7), sodium 135 mmol/l (137–145), potassium 4.1 mmol/l (3.5–5.0).

Headache occurs frequently in the population, and eight out of ten people report having experienced headache in the past year (1). Headache that is not caused by another disease is defined as primary. Secondary headaches are an expression of an underlying structural anomaly or disease, and make up less than 1 % of cases of headache in general practice (1). Acute headache is defined as an unusually severe headache with maximum intensity within 30 minutes of onset (2). It may be a symptom of an underlying serious pathology, such as acute cerebral haemorrhage, central nervous system infection or other structural pathology. Headache is a common reason for doctor visits and admission to neurological departments (2).

Our patient's clinical presentation with increasing headache over several days, normal preliminary neurological examination and normal laboratory tests suggested a primary headache.

The neurologist on duty concluded that the patient probably had tension headache and occipital nerve irritation. However, due to intense pain, nausea and vomiting, the patient was referred for acute computed tomography (CT) of the head to exclude intracranial space-occupying lesions. CT examination of the head three hours after admission revealed no pathology. The patient was given pain relief in the form of paracetamol 1 g per os and diclofenac 75 mg intramuscularly. She also received diazepam 5 mg per os and metoclopramide 10 mg intravenously because of agitation and nausea. Over the next couple of hours, she became increasingly lethargic and vomited several times. Given her worsening symptoms, we wished to exclude cerebral venous sinus thrombosis. Eight hours after admission, CT of the head was therefore performed with venous angiography, but provided no evidence for cerebral venous sinus thrombosis.

Two CT scans produced no relevant findings. The patient's condition deteriorated, and we wished to perform a lumbar puncture to assess the possibility of central nervous system infection, but the patient objected. Since she was afebrile and had normal infection parameters, it was not considered necessary to perform lumbar puncture on an agitated patient.

The patient became increasingly agitated and disoriented throughout the night. The altered mental status was attributed to diazepam administered in Acute Admissions, and an attempt was made to reverse the effects of diazepam by administering flumazenil intramuscularly, without notable effect. The neurologist on duty consulted with a psychiatrist by telephone. The

patient's condition was judged to be delirium triggered by severe headache, intake of analgesics and sedatives, in combination with the negative experience of acute hospitalisation. She was moved to a single room with continuous monitoring, and all medications were discontinued. The next day, she remained weak and disoriented and her GCS score decreased to 9 out of 15 (M 5+ V 2+ E 2). Tympanic temperature was measured at 38 °C. Fever and altered consciousness raised suspicion of infectious encephalitis. Infectious disease specialists were summoned to guide further assessment. Lumbar puncture was performed, which revealed leukocytes $128 \cdot 10^6/l$ (0–5.9), 99 % mononuclear cells, 1 % polymorphonuclear cells, glucose 4.6 mmol/l, protein 0.3 g/l (< 0.5) and cerebrospinal fluid/serum glucose ratio 0.7 (> 0.6). Antiviral treatment was initiated with acyclovir 10 mg/kg intravenously every 8 hours. Given the severe clinical picture, it was decided to also begin ceftriaxone 4 g x 1 intravenously and ampicillin 3 g x 4 intravenously since early-stage bacterial meningitis could not be ruled out. An electroencephalogram (EEG) 24 hours after admission showed non-specific activity, most pronounced in the left frontotemporal region, that could be consistent with encephalitis. Owing to a decreased level of consciousness and suspicion of infectious encephalitis, the patient was transferred to the intensive care department.

Cerebrospinal fluid analysis revealed elevated leukocytes, suggesting a central nervous system infection. The presence of fewer than 500 leukocytes, of which 99 % were mononuclear cells, pointed towards a viral aetiology, but alternative explanations could be neuroborreliosis, listeria infection, neurosyphilis or tuberculous meningitis. Another bacterial meningitis/early-stage meningoencephalitis could also have produced a similar picture, but an illness duration of several days and the relatively low leukocyte count in the cerebrospinal fluid argued against this. In bacterial meningitis/meningoencephalitis, low cerebrospinal fluid glucose and high cerebrospinal fluid protein would also be expected.

Serological assays for human immunodeficiency virus (HIV), varicella zoster virus (VZV), Epstein-Barr virus (EBV) and syphilis were requested. Cerebrospinal fluid was sent for microscopic examination and gram staining, bacteriological culture including tuberculosis, direct microscopy of acid-fast rods, and serological testing for intrathecal borrelia IgG and IgM antibodies. Nucleic acid amplification (PCR) of cerebrospinal fluid was performed for *Mycoplasma pneumoniae*, *Mycobacterium tuberculosis*, herpes simplex virus (HSV) types 1 and 2, varicella zoster virus, enterovirus, human herpesviruses 6 and 7, Epstein-Barr virus and cytomegalovirus (CMV). Based on the patient's travel history, thick and thin blood smears for malaria diagnosis, and a rapid test for detection of dengue virus antigen/antibody in serum, were requested from a local laboratory; both tests yielded negative results. A serum sample was sent to the Norwegian Institute of Public Health (NIPH) the next day to be tested for Japanese encephalitis, and for West Nile, dengue and chikungunya viruses, as well as for tick-borne encephalitis (TBE) virus. Cerebrospinal fluid was not sent to the NIPH for examination as this diagnostic option was not considered at the time. Blood cultures were not requested during the patient's initial fever while in the neurological department.

MRI of the head was performed three days after admission to look for signs of organ affection or findings that could be consistent with herpes virus encephalitis. The MRI was described as normal. The patient was observed for 24 hours in the intensive care department. The following day she was alert and oriented, but with amnesia for the recent course of events. She was transferred to the Department of Infectious Diseases, and antibacterial medications were discontinued after three days of treatment. Since PCR testing of cerebrospinal fluid was negative for herpes and varicella viruses, acyclovir was discontinued after five days of treatment.

After seven days in hospital, her condition was greatly improved and she was discharged without further pharmaceutical treatment, with an appointment for outpatient follow-up ten days later.

All tests were negative, with the exception of the serological analysis performed at the NIPH, for which results only became available post-discharge.

Immunofluorescence (IF) assays detected IgM and IgG antibodies against dengue virus in serum samples collected one and three weeks after symptom onset respectively, the latter in connection with the outpatient follow-up. Stably elevated IgG antibodies > 1: 1000 (cut-off 1: 100) were detected against all subtypes of dengue virus in both the acute and convalescent samples, but only IgM antibodies against dengue virus subtype 3 > 1: 100 (cut-off 1: 10), plus a somewhat weaker response against subtype 2 (> 1: 10). IgG antibodies against TBE virus and Japanese encephalitis virus were detected at lower titres (> 1: 100) and are therefore most likely cross-reactive antibodies from prior infections or vaccination. The patient stated that she had been vaccinated against Japanese encephalitis as a child. On the basis of serological findings in the acute and convalescent serum samples, with elevated IgG antibodies against all subunits of dengue virus and IgM antibodies against subtype 3, we concluded that current or recent dengue fever subtype 3 infection was the most likely cause of the encephalitis.

Dengue virus is an RNA virus in the *flaviviridae* family and is the cause of one of the most common mosquito-borne infectious diseases worldwide, with approximately 50 million cases per year. There are four subtypes of dengue virus, all of which give rise to a similar clinical picture with symptoms including fever, headache, rash and body aches [\(3\)](#).

The NIPH receives reports of 57–98 imported cases of dengue fever annually, most frequently in the age group 20–49 years and in travellers returning from Thailand. In 2010, a fatal case in a Norwegian woman of dengue haemorrhagic fever imported from Thailand was also reported to the Norwegian Surveillance System for Communicable Diseases (MSIS) [\(4\)](#). Based on travel history, clinical assessments and detection of specific IgM antibodies against dengue virus in serum, our case history probably represents the second case of dengue fever with central nervous system affection since mandatory reporting to the MSIS database was introduced in Norway on 1 July 2012 [\(5\)](#).

Upon telephone follow-up ten months after discharge, the patient was in full-time employment and reported no late effects.

Discussion

This case history demonstrates that it may be difficult to distinguish encephalitis from other common clinical conditions early in the disease course, especially in the absence of signs of infection. A diagnosis of encephalitis is made on the basis of medical history, clinical findings and supplementary examinations (Table 1) (6). Upon admission, our patient fulfilled none of the clinical criteria for encephalitis. Only when the patient developed a fever and altered consciousness was infectious encephalitis suspected. At that point, she fulfilled the major criterion and three minor criteria.

Table 1

Diagnostic criteria for encephalitis. For a diagnosis to be made, the major criterion and at least three minor criteria must be fulfilled (6)

Major criterion	Altered mental status lasting ≥ 24 hours with no alternative cause identified
Minor criteria	1. Fever ≥ 38 °C within 72 hours before or after symptom onset
	2. Generalised or partial seizures (not due to pre-existing epilepsy)
	3. New-onset focal neurological deficits
	4. Cerebrospinal fluid: ≥ 5 leukocytes per mm ³
	5. Radiological findings, suggestive of encephalitis
	6. EEG changes consistent with encephalitis and not attributable to another cause

Most patients with infectious encephalitis have fever, and more than half have headache. Neck stiffness (in cases of meningoencephalitis), seizures, changes in consciousness or personality, and focal neurological deficits may occur (7).

In such cases, EEG may be a useful and important supplementary test to strengthen the suspicion of cerebral pathology. An MRI scan may be indicated upon suspicion of herpes simplex encephalitis since a specific pattern of changes is typically seen (8). Antibody assays and direct detection of causative agents (PCR) yielded negative results for the most common causes of encephalitis in Norway. The patient's travel history therefore played a key role in guiding further assessments.

The patient became ill seven days after returning from Sri Lanka, where she had stayed for three weeks. An incubation period of 4–7 days for dengue virus (varies between 3–14 days) would be consistent with her medical history. Direct detection of the causative agent (antigen or nucleic acid detection) is recommended, but requires appropriate samples (blood, urine and cerebrospinal fluid) to be collected early in the acute phase since the viraemic phase is short-lived (Figure 1).

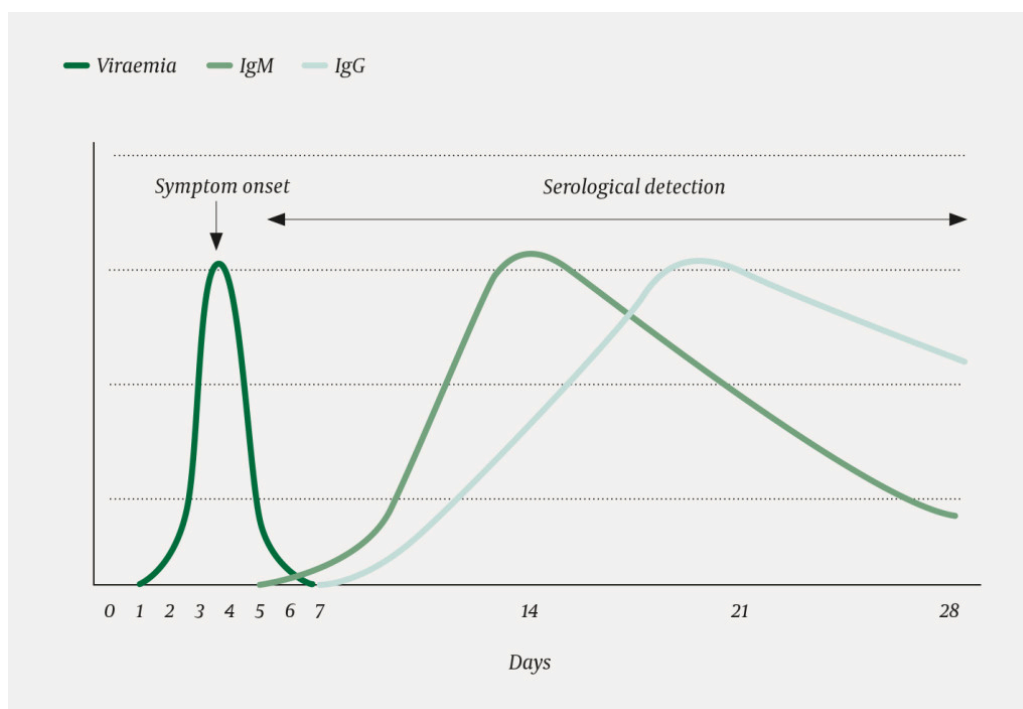


Figure 1 Viraemic phase and antibody detection upon infection with dengue virus. The figure is based on a sketch by Susanne Gjeruldsen Dudman, Norwegian Institute of Public Health

Several hospitals offer rapid tests for qualitative detection of dengue virus (antibody/antigen) in blood, but these rapid tests generally have a low sensitivity of about 60–70 % (5, 9). Both negative and positive results should therefore be confirmed with more sensitive and specific tests. The dengue rapid test performed at a primary hospital yielded negative results, and the serum sample was sent to the NIPH for further confirmation. The non-specific nature of early symptoms of neuroinvasive viral infection may result in lumbar puncture being delayed or not performed at all. Antibody detection in serum is therefore often the only option for more precise identification of the causative agent. Testing of paired sera from acute and convalescent samples to determine whether significant increases in IgG titre have occurred is important when investigating possible dengue virus infection (9). Figure 1 illustrates how IgG antibodies follow a few days after IgM when the viraemic phase is over, and may persist for many years. Isolated detection of IgM antibodies in serum may reflect cross-reactive antibodies or non-specific binding. The finding must therefore be confirmed in a new sample taken 2–3 weeks later, to demonstrate development of a specific IgG antibody response. By contrast, detection of IgM antibodies against dengue virus in cerebrospinal fluid has higher specificity and suggests current infection, but has lower sensitivity (10, 11).

High IgG titres in the acute sample taken one week after symptom onset indicate that our patient may previously have been infected with dengue virus and that the current infection was a secondary dengue virus infection. Detection of simultaneous IgM and IgG in the acute sample as described in our case history is a fairly typical pattern in secondary dengue virus infection, although it is not uncommon for the IgM response to be completely absent (12). The absence of other pertinent neuroinvasive agents lends further support to our diagnosis (13).

Encephalitis is a relatively common clinical picture in cases of dengue virus infection with central nervous system affection (14). Both primary and secondary dengue virus infection may lead to encephalitis. Subtype 3 is most frequently associated with neurological complications, including encephalitis (15). Dengue virus encephalitis may be associated with a severe disease course and neurological sequelae (16). The World Health Organisation (WHO) has included the criteria for dengue virus encephalitis and recommended diagnostics and treatment in its 2009 guidelines (3). There is no specific antiviral treatment for dengue fever, but symptomatic treatment and fluid therapy may be crucial in more severe disease courses such as haemorrhage and encephalitis. Uncomplicated dengue fever requires no specific follow-up.

Conclusion

Although dengue fever is a relatively common cause of imported fever among travellers returning to Norway, encephalitis is a very rare complication. When cerebral malaria has been excluded, dengue virus, in common with other neuroinvasive viruses, should be considered a possible cause of central nervous system infections after travels in tropical/subtropical regions.

The patient has consented to the publication of this article.

LITERATURE

1. Løge I. Hodepine. Norsk Elektronisk Legehåndbok 2016. <https://legehandboka.no/handboken/kliniske-kapitler/nevrologi/symptomer-og-tegn/hodepine/> (24.2.2017).
2. Torelli P, Campana V, Cervellin G et al. Management of primary headaches in adult Emergency Departments: a literature review, the Parma ED experience and a therapy flow chart proposal. *Neurol Sci* 2010; 31: 545 - 53. [PubMed][CrossRef]
3. World Health Organization. Dengue guidelines for diagnosis, treatment, prevention and control. Geneva, 2009. <http://www.who.int/tdr/publications/documents/dengue-diagnosis.pdf> (18.1.2017).
4. Vainio K, Noraas S, Holmberg M et al. Fatal and mild primary dengue virus infections imported to Norway from Africa and south-east Asia, 2008-2010. *Euro Surveill* 2010; 15: 19666. [PubMed][CrossRef]
5. Folkehelseinstituttet. Smittevernveilederen. Denguefeber – veileder for helsepersonell. <https://www.fhi.no/nettpub/smittevernveilederen/sykdommer-a-a/denguefeber/> (18.1.2018).

6. Venkatesan A, Tunkel AR, Bloch KC et al. Case definitions, diagnostic algorithms, and priorities in encephalitis: consensus statement of the international encephalitis consortium. *Clin Infect Dis* 2013; 57: 1114 - 28. [PubMed][CrossRef]
 7. Granerod J, Ambrose HE, Davies NW et al. Causes of encephalitis and differences in their clinical presentations in England: a multicentre, population-based prospective study. *Lancet Infect Dis* 2010; 10: 835 - 44. [PubMed][CrossRef]
 8. Bhoi SK, Naik S, Kumar S et al. Cranial imaging findings in dengue virus infection. *J Neurol Sci* 2014; 342: 36 - 41. [PubMed][CrossRef]
 9. Centers for Disease Control and Prevention (CDC). Clinical & Laboratory guidance. Dengue Fever. <https://www.cdc.gov/dengue/clinicallab/index.html> (16.1.2018).
 10. Wang WK, Chen HL, Yang CF et al. Slower rates of clearance of viral load and virus-containing immune complexes in patients with dengue hemorrhagic fever. *Clin Infect Dis* 2006; 43: 1023 - 30. [PubMed][CrossRef]
 11. Domingues RB, Kuster GW, Onuki-Castro FL et al. Involvement of the central nervous system in patients with dengue virus infection. *J Neurol Sci* 2008; 267: 36 - 40. [PubMed][CrossRef]
 12. Halstead SB. Dengue. *Lancet* 2007; 370: 1644 - 52. [PubMed][CrossRef]
 13. Varatharaj A. Encephalitis in the clinical spectrum of dengue infection. *Neurol India* 2010; 58: 585 - 91. [PubMed][CrossRef]
 14. Jackson ST, Mullings A, Bennett F et al. Dengue infection in patients presenting with neurological manifestations in a dengue endemic population. *West Indian Med J* 2008; 57: 373 - 6 [PubMed].. [PubMed]
 15. Solomon T, Dung NM, Vaughn DW et al. Neurological manifestations of dengue infection. *Lancet* 2000; 355: 1053 - 9. [PubMed][CrossRef]
 16. Wasay M, Channa R, Jumani M et al. Encephalitis and myelitis associated with dengue viral infection clinical and neuroimaging features. *Clin Neurol Neurosurg* 2008; 110: 635 - 40. [PubMed][CrossRef]
-

Publisert: 18 May 2018. Tidsskr Nor Legeforen. DOI: 10.4045/tidsskr.17.0444

Received 14.5.2017, first revision submitted 17.10.2017, accepted 13.2.2018.

© Tidsskrift for Den norske legeforening 2025. Downloaded from tidsskriftet.no 31 December 2025.