

---

# Internal abdominal hernia

---

## IMAGES IN MEDICINE

MAGNUS BERLE

E-mail: [magnus.berle@gmail.com](mailto:magnus.berle@gmail.com)

Department of Abdominal and Emergency Surgery

Haukeland University Hospital

and

University of Bergen

Magnus Berle (born 1983), PhD and specialty registrar.

The author has completed the ICMJE form and reports no conflicts of interest.

KRISTINE HERMANSEN DAHLSLETT

Department of Radiology

Haukeland University Hospital

and

Hospital of Southern Norway, Arendal

Kristine Hermansen Dahlslett (born 1982), acting senior consultant and specialty registrar.

The author has completed the ICMJE form and reports no conflicts of interest.

GIEDRE KAVALIAUSKIENE

Department of Radiology

Haukeland University Hospital

Giedre Kavaliauskiene (born 1980), senior consultant.

The author has completed the ICMJE form and reports no conflicts of interest.

DAG HOEM

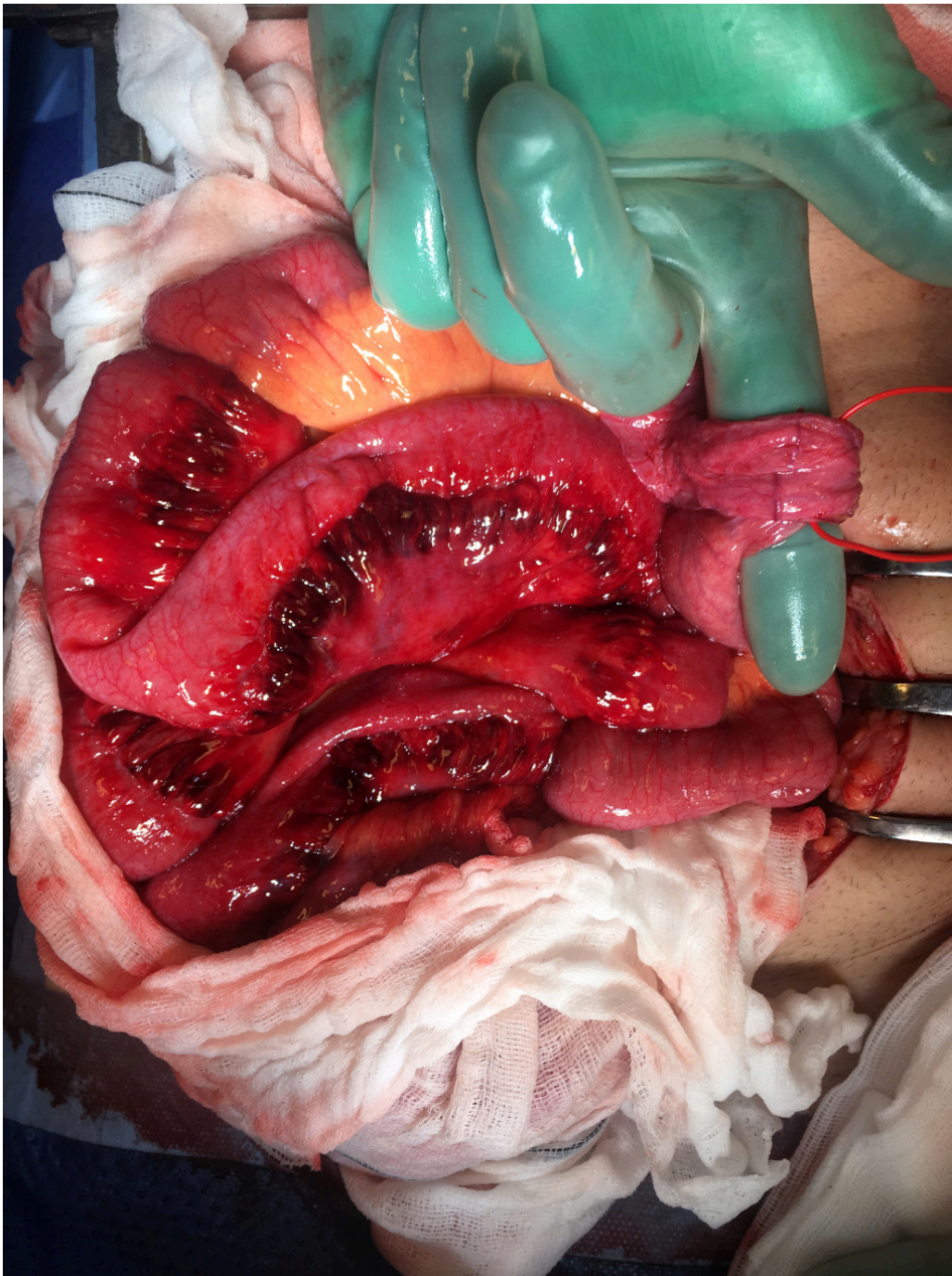
Department of Abdominal and Emergency Surgery

Haukeland University Hospital

Dag Hoem, PhD and senior consultant.

The author has completed the ICMJE form and reports no conflicts of interest.

---



A previously healthy man in his twenties was hospitalised in the general surgical ward with pains located in the central abdomen. Routine blood tests and vital signs were unremarkable. The pains subsided, and he was discharged the same evening with an agreement for open readmission. Following discharge from the hospital, the pains were moderate for the first two days. On the third day he awoke with severe abdominal pain. During hospital examination on the same day, he was nauseated. His abdomen was slightly distended and he had tenderness on palpation of the right iliac fossa. Routine blood tests were still unremarkable.

A CT scan of the abdomen showed herniated small intestinal loops through a hernial port in the mesentery, which was perceived as an internal hernia.

He underwent laparoscopic surgery that was converted to open surgery, as the intestine could not be repositioned laparoscopically. The small intestine was herniated into a peritoneal pocket approximately 15 cm distal to the ligament of Treitz. A full one metre of small intestine lay within a peritoneal hernial sac in an intramesenteric hernia. The image shows the hernial sac around the finger and the small intestine with oedema in the mesentery. Slight discolouration of the intestine itself, consistent with a partial obstruction of the circulation, can also be observed. The hernia port and sac protruding from the peritoneum were resected. The patient was discharged on the fourth postoperative day in good general condition.

Internal abdominal hernia is a clinically difficult diagnosis due to diffuse symptoms and scant findings on clinical examination. The main symptom is intermittent signs of intestinal obstruction, but acute abdominal pain is also possible. The condition can be identified by a CT scan or diagnostic laparoscopy. Internal abdominal hernia constitutes 0.5 – 5.8 % of cases of intestinal obstruction, while intramesenteric hernia is an uncommon variant (1–3).

---

*The patient has consented to the publication of this article.*

---

## LITERATURE

1. Doishita S, Takeshita T, Uchima Y et al. Internal hernias in the era of multidetector CT: Correlation of imaging and surgical findings. Radiographics 2016; 36: 88 - 106. [PubMed][CrossRef]
2. Martin LC, Merkle EM, Thompson WM. Review of internal hernias: radiographic and clinical findings. AJR Am J Roentgenol 2006; 186: 703 - 17. [PubMed][CrossRef]
3. Crispín-Trebejo B, Robles-Cuadros MC, Orendo-Velásquez E et al. Internal abdominal hernia: Intestinal obstruction due to trans-mesenteric hernia containing transverse colon. Int J Surg Case Rep 2014; 5: 396 - 8. [PubMed][CrossRef]

---

Publisert: 4 September 2017. Tidsskr Nor Legeforen. DOI: 10.4045/tidsskr.17.0090

Received 25.1.2017, first revision submitted 31.3.2017, accepted 24.4.2017.

Copyright: © Tidsskriftet 2026 Downloaded from tidsskriftet.no 12 February 2026.